

## A very late-onset deep infection after prosthetic inguinal hernia repair

V. Genç<sup>1</sup>, C. Ensari<sup>2</sup>, Z. Ergul<sup>2</sup>, H. Kulacoglu<sup>2</sup>

<sup>1</sup>Department of Surgery, Ankara University, Medicine Faculty, Ankara Turkey

<sup>2</sup>Department of Surgery, Diskapi Teaching and Research Hospital, Ankara Turkey

### Rezumat

#### *Infecție profundă tardivă după cura herniei inghinale cu proteză*

Cura herniei inghinale cu proteză, în practica curentă, are o rată mică de recurență și infecție. Totuși, infecția locală este o potențială complicație. Până în prezent au fost raportate un număr mic de cazuri de infecție profundă tardivă a plasei după cura herniei cu proteză. Raportăm un nou caz de infecție postherniorafie cu instalare foarte tardivă.

**Cuvintele cheie:** hernie inghinală, plasaă, infecție profundă, infecție tardivă, excizia plasei

### Abstract

Prosthetic repair of inguinal hernias has low recurrence and infection rates in practice. However, surgical site infection is still a potential complication. A limited number of cases have been reported to date describing late-onset deep mesh infection following prosthetic repairs. We herein report a new case of postherniorrhaphy infection with a very late onset.

**Key words:** inguinal hernia, mesh, deep infection, late infection, mesh removal

### Introduction

The use of prosthetic materials for hernia repair is now a common approach worldwide. The technique is simple, rapid, less painful, more comfortable and more effective. (1) It has very low recurrence rates in many centers with acceptably low infection rates. However, surgical site infection is still a potential complication. In fact, most postherniorrhaphy infections are superficial and usually encountered in the early postoperative period. (2) Nevertheless, a limited number of cases have been reported to date describing late-onset deep mesh infection following prosthetic repairs of inguinal hernias. (3-5) We herein report a new postherniorrhaphy infection case with a very late onset.

### Case Report

*A 65-year old male patient admitted to hospital with general fatigue, inguinal swelling and localized hyperemia. He had an open repair with polypropylene mesh for a right-sided indirect inguinal hernia sixty-one months ago. Antibiotic prophylaxis with 1,5 g ampicillin and sulbactam (Duocid 1 g IV, Pfizer Inc., Istanbul, Turkey) was given before the incision. The patient's file was found and reviewed: It was Lichtenstein technique employed with a standard polypropylene mesh (Auto-Suture; Norwalk, CT, USA). The patient was discharged after an uneventful postoperative course.*

*In physical examination, the patient had a normal temperature and multiple palpable inguinal lymphadenopathies. The swelling was firm and painful, and the overlying skin was red in color (Fig. 1). There was a mild leukocytosis ( $13.2 \times 10^9$  cells/L) with a sedimentation rate of twice its upper limit. Ultrasound showed a 31x12 mm cavity that contained fluid like hypoanechoic pus. Abdominal-pelvic computed tomography*

Corresponding author:

Volkan Genç MD.  
Çiğdem Mah. 28. cad. 13/23, 06520  
Çankaya Ankara Turkey  
Tel.: +90 312 3103333- 2676  
Fax: +90 312 3103989  
E-mail: volkan@medicine.ankara.edu.tr

demonstrated a pre-peritoneal mass closely adhering to the small bowel (Fig. 2).

A surgical exploration and drainage was planned with a diagnosis of inguinal sepsis. Pus was drained and the mesh was removed (Fig. 3). The wound was left open for secondary healing. Methicilline resistant staphylococcus aureus was isolated from culture. We didn't use oral and/or intravenous antibiotic for the patient's treatment. The wound was irrigated with saline and dressed with antibacterial pomade daily. The wound completely healed at 2 months. No sign of hernia recurrence was detected 6 months postoperatively.

## Discussion

Wound infection after inguinal hernia repair is a potential complication and occurs in less than 5% of patients. (6) It is usually encountered in the early postoperative period. However when a prosthetic material is used the term of postoperative infection points the whole first postoperative year. After that time any surgical site infection is considered as "late-onset". Deep surgical site infection is not frequent but obviously a more serious entity than a superficial infection. It may cause groin sepsis and a need for mesh removal.

The use of antibiotic for surgical site infection prophylaxis for a "clean" surgical procedure like herniorrhaphy is controversial. Yerdel et al (7) and Lazorthes et al (8) found antibiotic prophylaxis may be of benefit in hernia repairs with prosthetic material, but Aufenacker et al (9) and Tzovaras et al (10) failed to confirm that. On the other hand, Cochrane database is not in favor of the administration of antibiotic prophylaxis (6), contrary to a recent meta-analysis from Bogotá, Colombia (11), which analyzed 6 randomized clinical trials using the same criteria with Cochrane Collaboration.

Prophylactic antibiotic administration probably does not affect a late infection after one year of surgery. Besides, a late infection is influenced by the use of mesh, while an early wound infection following hernia repair do not seem to be related to that. (2) In a 14 cases series of deep mesh infection no patients had any evidence of wound infection at the time of discharge. (4) Similarly, no early surgical site infection was recorded in the present case. Therefore, no relationship between early and late infection can be asserted.

A limited number of cases have been reported in the literature to date describing late-onset deep mesh infection following open (3) and laparoscopic (5) inguinal hernia repairs. The longest interval in the literature is 49 months. (4) The present case reported here seems to have the latest one with its 61-month very long interval between the index operation and mesh removal procedure. We now know that deep prosthetic infection can be met even after the 5th postoperative year, and possibly there is no limitation for its timing.

Delikoukos et al (3) revealed the late onset mesh infection did not correlate to either type of prosthetic material inserted or the suture material used. Removal of the complete or partial prosthetic mesh material is usually required to control the infection. Hernia recurrence is a concern after removing the mesh for an eventual infection control. Fawole et al

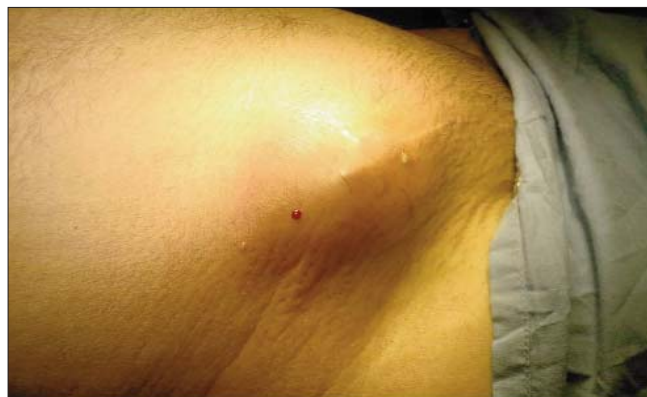

Figure 1. The gross view of swelling

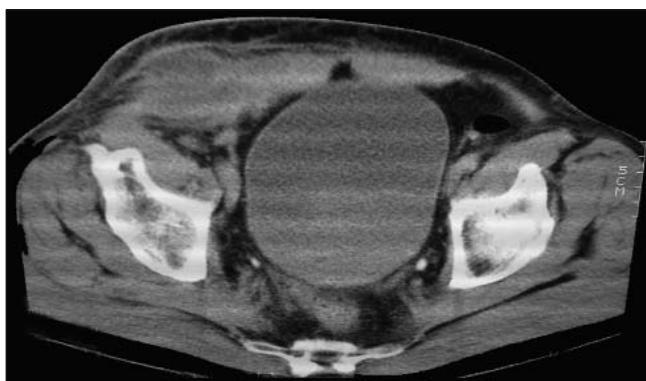

Figure 2. CT shows a preperitoneal mass about 3 cm in diameter

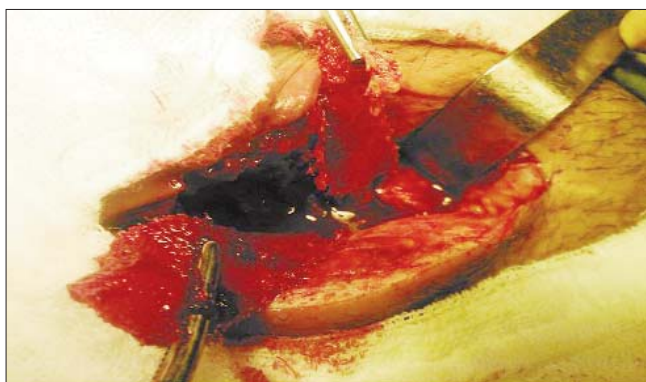


Figure 3. Intraoperative photograph of meshoma

reported that recurrence is not the rule in those cases. (3) Only two patients out of their 14 cases developed recurrence after mesh removal within a median follow-up of 44 months. The present case also has not developed recurrence within 6 months following mesh removal.

With the increasing use of prosthetic materials in hernia repairs, the number of patients with late mesh infections is likely to increase by time. The diagnosis may be rather effortless with patient history and inguinal incision scar, and the treatment should consist of mesh removal and drainage if needed without a concern of hernia recurrence.

## References

1. Lichtenstein IL, Shulman AG, Amid PK, et al. Am J Surg 1989;157:188-193.
2. Mann DV, Prout J, Havranek E, et al. Late-onset deep prosthetic infection following mesh repair of inguinal hernia. Am J Surg 1998;176:12-14.
3. Delikoukos S, Tzovaras G, Liakou P, et al. Late onset deep mesh infection after inguinal hernia repair. Hernia 2007;11:15-17.
4. Fawole AS, Chaparala RP, Ambrose NS. Fate of the inguinal hernia following removal of infected prosthetic mesh. Hernia 2006;10:58-61.
5. Hofbauer C, Andersen PV, Juul P, et al. Late mesh rejection as a complication to transabdominal preperitoneal laparoscopic hernia repair. Surg Endosc 1998;12:1164-1165.
6. Sanchez-Manuel FJ, Lozano Garcia J, Seco-Gil JL. Antibiotic prophylaxis for hernia repair. Cochrane Database Syst Rev 18(3): CD003769, 2007.
7. Yerdel MA, Akin EB, Dolalan S, et al. Effect of single-dose prophylactic ampicillin and sulbactam on wound infection after tension-free inguinal hernia repair with polypropylene mesh. Ann Surg 2001;233:26-33.
8. Lazorthes F, Chiotasso P, Massip P, et al. Local antibiotic prophylaxis in inguinal hernia repair. Surg Gynecol Obstet 1992;175:569-570.
9. Aufenacker TJ, Geldere D, Mesdag T, et al. The role of antibiotic prophylaxis in prevention of wound infection after Lichtenstein open mesh repair of primary inguinal hernia. Ann Surg 2004;240:955-961.
10. Tzovaras G, Delikoukos S, Christodoulides G, et al. The role of antibiotic prophylaxis in elective tension-free mesh inguinal hernia repair: results of a single-centre prospective randomised trial. Int J Clin Pract 2007;61:236-239.
11. Sanabria A, Domínguez LC, Valdivieso E, et al. Prophylactic antibiotics for mesh inguinal hernioplasty: a meta-analysis. Ann Surg 2007;245:392-396.